

3793.9

Very good. You have done a lot  
of research and fact  
finding.

M. Dobbyn

7:10

## CASE HISTORY

### OPHTHALMICS

(A+)

Jane Brown

12 yrs

Female

Single

Anglican

children's ward

Student

Date admitted 9-5-72. Discharged 13-5-72

Diagnosis on admission - Strabismus Rt eye

Diagnosis on discharge - Recession Rt.  
lateral Rectus.

### Appearance of Pt. on Admission

Healthy but apprehensive looking girl,  
admitted for theatre tomorrow.

### Observations on Admission

T 36<sup>9</sup> P 112 R 24

Weight 6 stone 1 lb.

Urine test NAD.

### Family History

Mother 46 yrs, healthy, wears glasses  
for reading & longer distance.

Father 50 yrs healthy.

Sister 20 yrs healthy.

Sister 18 yrs healthy - wore glasses  
when a young child & did corrective  
exercises for strabismus of Lt. eye.

Sister 16 yrs healthy.

Sister 10 yrs healthy.

### Previous History

Squint Repair at 5 yrs, of Lt eye.

~~Usual childhood diseases~~ - mumps,  
measles, chicken pox

At age of 18/12, Jane's mother noticed  
both eyes were abducting at times.  
She was taken to a specialist on  
numerous occasions to be told there

was nothing wrong.

Still noticing strabismus at 5 yrs, Jane's mother took her back to the specialist where Jane she was taken into an artificially lit surgery, where again eyes appeared normal. At the request of Jane's mother, the curtains were drawn back, letting natural light into the room, allowing the abnormality to appear.

Following this, tests were done, orthoptic evaluations to measure the angle of strabismus under different conditions necessary to determine the method of surgical correction. During this evaluation, stereoscopic slides were used. Each of the two pictures is incomplete, & failure to use both eyes was recognised by Jane stating what she saw, & the Dr. working on what parts were missing.

Not long afterwards, Jane was admitted to hospital to have correction of convergent Lt. strabismus, which was successful.

Jane's mother was told that the right eye may need repair at a later stage.

#### Present History.

Convergent right eye noted to be becoming worse 6/12 ago.

Jane returned to the specialist where tests were repeated.

Eyes were rotated through the 6 cardinal points.

A drop of atropine 0.5% was used to dilate the pupil.

A prism, or triangular lens was also used to determine the angle of deviation.

3<sup>mm</sup>

3793.9

m. Dolhyn

Admitted to Children's Ward for elective surgery to Rt. eye.

Admitted one day preoperatively.

Rx on admission

cut eyelashes

Guttae chloramphenicol 0.5% to both eyes 4hrly.

Jane was placed in a room with other children her own age.

Mogadon xi given nocte to settle per Rx.

Fasted from 12 mn after glucose drink.

Jane was prepared for general anaesthetic, sign-forms signed, dressed in theatre clothes, + premedication of Pethidine 50mg IM Atropine 0.6mg IM was given 1 hr preoperatively.

She was transferred to theatre, where the operation of Recession of Rt Lateral Rectus, was performed.

She returned to the ward, conscious + satisfactory, placed in semi-recumbent position.

Colour - good.

Observations were taken ½ hrly, then 4hrly, P+R + check for haemorrhage.

Eye pad in situ to deter Jane from rubbing the eye.

Diet - as desired.

Post Operative Rx 1. Bed rest - toilet privileges

2. Panadol 10ml 4hrly PRN

3. Dressing tomorrow

morning ± guttae chloramphenicol 0.5%.

There were no restrictions on reading, or watching T.V. etc.

Plain catgut suture was used in the operation, so there was no need to remove any sutures.

On the first morning post operatively, the dr. visited, checked the eye for haemorrhage, + that both eyes were straight.

He then allowed Jane to be discharged

& asked for her to visit him in two days at his surgery.

Now Jane's eyes look perfect, & you wouldn't know she'd had the operations. She is, however, still able to adduct her right eye at will, while keeping the left eye straight.

### Appendix

Strabismus - when one eye is not directed at the object of attention, the right or left eye may be constantly deviated, or the deviation may alternate between the right & left eye.

#### Causes -

- 1 Paresis of an extraocular muscle.
- 2 Hypermetropia
- 3 Muscle imbalance plus absence of fusion - as in Jane's case.
- 4 Muscle imbalance plus breakdown of fusion - as in Jane's case.
- 5 Defective vision in one eye, plus muscle imbalance.

#### Treatment -

- 1 Glasses to correct refractive error
- 2 Occlusion of fixing eye to strengthen deviating eye.
- 3 Fusion training - to teach the fusion of each eye into a single image.
- 4 Operation - The attachments of the muscles to the globe are altered to put the eyes parallel to each other.

Eye Lashes - It is not necessary to cut the lashes for extra-ocular surgery. This is dr.'s preference.

Chloromycetin - an antibiotic given prophylactically here.

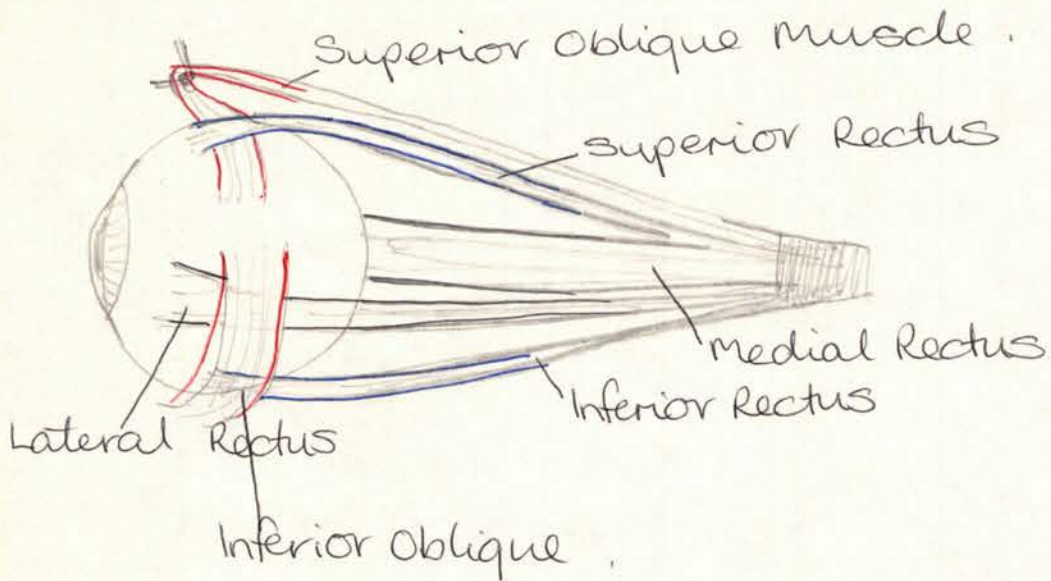
Atropine - A mydriatic to dilate the pupil.

References

- Ophthalmology - Duguid + Berry.  
Lectures in diseases of the eye - Royal Vic.  
Eye + Ear Hospital.  
Anatomy + Physiology - Ross + Wilson.

Thanks to Mildura Base Hospital for lending patient's history, & also to patient's mother for her help.

Applied Anatomy and Physiology: (Relevant Diagrams)



Extrinsic Muscles of the Eye .



m. Solihujh

3793-9

HEAD INJURY RECORD PROGRESS SHEET.

NAME Jane Brown RECORD NUMBER \_\_\_\_\_  
 AGE 13 yrs MEDICAL OFFICER Dr Specialist.  
 WARD 5 DATE ADMITTED 9/5/72

PROVISIONAL DIAGNOSIS

Recession Rt Lateral Rectus

DATE	TIME	STATE OF CONSCIOUSNESS	PULSE	RESP.	BLOOD PRESSURE	PUPILS		REACTION	
						R.	L.	R.	L.
10/5/72 Ward	9.20 am	colour-pale conscious-sleeping	112	30					eye pad in situ Rt eye
	10 am		116	28	"	"	"	"	
	10.30	awake	124	26					
	11 am	awake	122	20	"	"	"	"	
	11.30	sleeping	118	20					
	12.30	"	102	24	"	"	"	"	
	12.30	"	112	22					
	1 pm	awake	110	20	"	"	"	"	
	1.30	sleeping	98	22					
	Recovery Room								
	9.05	semi-consc.	116	20					
	9.10	colour ✓ resp ✓ cons. + satisfactory							Pad to eye
	9.15	RTW consc + satisfactory.							